

## Borderline and Precursor Lesions of Thyroid Neoplasms: A Missing Link

Kennichi Kakudo<sup>1\*</sup>, Tomoko Wakasa<sup>1</sup>, Mariko Kakudo<sup>2</sup> and Zhiyan Liu<sup>3</sup>

<sup>1</sup>Department of Pathology and Laboratory Medicine, Nara Hospital Kinki University Faculty of Medicine, Ikoma, Japan; <sup>2</sup>Department of Clinical Genetics, Hyogo College of Medicine, Nishinomiya-city, Japan; <sup>3</sup>Department of Pathology and Pathophysiology, Shandong University School of Medicine, Jinan, China.

*Journal of Basic & Clinical Medicine 2015, 4(1):2-7*

### Abstract

There are several thyroid lesions that have been reported to be precursor, precancerous, or premalignant forms of, or predisposing factors for thyroid carcinoma. These lesions include normal thyroid with radiation history and chronic inflammation such as autoimmune thyroiditis, solid cell nest, hyperplastic adenomatous nodule, dyshormonogenetic goiter, follicular adenoma, atypical adenoma, borderline malignancy (follicular tumor of uncertain malignant potential and well-differentiated tumor of uncertain malignant potential), and some extremely low-grade thyroid neoplasms currently labeled as cancer including papillary microcarcinoma, capsular invasion only follicular carcinoma, and encapsulated papillary carcinoma. This article briefly reviews these lesions as possible precursor lesions of thyroid carcinomas, an important initial step of carcinogenesis or an early phase of progression in the multistep carcinogenesis theory.

**Keywords:** Thyroid gland, follicular cell, borderline malignancy, precancerous lesion, precursor lesion, carcinogenesis

### I. Precursor Lesions of Thyroid Carcinoma: A Missing Link

A number of sequential events and multiple steps of thyroid carcinogenesis and corresponding genetic and epigenetic alterations, from normal follicular cells, benign proliferative lesions, benign follicular adenoma (FA), well-differentiated carcinoma (WDC), to poorly differentiated carcinoma (PDC) and undifferentiated carcinoma (UC) of thyroid, have not yet been fully elucidated (1-11). One of the major problems in adapting thyroid neoplasms into the multistep carcinogenesis model is the lack of known precursor lesions, a missing link of thyroid carcinogenesis in the multistep carcinogenesis theory (12). FA is described as a possible candidate for precursor lesions of thyroid carcinomas in many reviews and textbooks because of their morphological similarity and their common genetic alterations (*RAS* mutations and *RET/PTC* and *PAX8/PPAR $\gamma$*  rearrangements) (2-5, 8-11, 13-15). However, FA is not regarded as a high-risk precancerous lesion of follicular thyroid carcinoma (FTC) or papillary thyroid

carcinoma (PTC), and prophylactic surgery for benign FA is not currently recommended due to infrequent progression from FA to malignant neoplasms (16-19). Furthermore, in the WHO blue book it is explained that no definite precursor lesions are known for FTC, followed by a comment that FTC may arise from FA (20). Concerning PTC, it also stated that there is no known precursor lesion for it (20). As such, no definite precursor lesions for thyroid follicular cell carcinomas are currently known, while C-cell hyperplasia or C-cell carcinoma *in situ* is accepted as a precursor lesion for C-cell (medullary) carcinoma of the thyroid (21-24). This review analyzes the literature, highlights the possible precursor lesions for thyroid carcinoma in addition to FA, and clarifies the initiation and early progression phases in the multistep carcinogenesis of thyroid follicular cell neoplasms.

### II. Genetic Alteration in Morphologically Normal Looking Thyroid

Radiation is one of the risk factors of thyroid cancer, the evidence for which has been obtained from a sad history of medicine on childhood irradiation for benign diseases, nuclear accidents in nuclear power plants and the use of atomic bombs. Abend et al. evaluated gene expression profiles in 63 paired RNA specimens from normal and tumor tissues of patients who experienced the Chernobyl nuclear power plant accident during childhood (25). They concluded that the multistep process of radiation carcinogenesis begins in histologically normal thyroid tissue and may involve dose-dependent gene expression changes (25).

### III. Chronic Inflammation and Autoimmune Hashimoto's Thyroiditis Predispose to Papillary Carcinoma

Chronic inflammation is regarded as a possible preneoplastic condition in several organs including the thyroid gland, and Hashimoto's chronic thyroiditis has been reported to be a high-risk condition for PTC and malignant lymphoma (26-36). Di Pasquale et al. analyzed PTC with Hashimoto's thyroiditis and found that, of the four atypical solid microscopic nodules composed of cells with clear nuclei and occasional grooves without nuclear pseudoinclusions, two were associated with PTC and the other two not. They demonstrated cytoplasmic reactivity for cytokeratin 19 and RET/PTC antibody in two of the three cases examined, and concluded that these atypical nodules may represent a precursor lesion of PTC in patients with Hashimoto's thyroiditis (29). Chiu et al. analyzed a large number of cases with thyroiditis; the follicular epithelial dysplasia was positively stained for TTF1 and thyroglobulin, and some of them also expressed p63 (26%),

Accepted in December, 2014

\*Correspondence author: Kennichi Kakudo, Department of Pathology and Laboratory Medicine, Nara Hospital Kinki University Faculty of Medicine, Otoda-cho, 1248-1, Ikoma-city 630-0293, Japan,  
E-mail address: kakudo@thyroid.jp

HBME-1 (86%), CK19 (96%), galectin-3 (40%) and cyclin D1 (76%) (34). They concluded that atypical microscopic lesions in chronic thyroiditis with an immunohistochemical profile similar to PTC are premalignant lesions preceding PTC (34).

Multifocal fibrosing thyroiditis (MFT) has been proposed as a risk factor for PTC, however Frank et al. analyzed *BRAF* mutations in seven cases of PTC with MFT but found none. They concluded that there is no evidence suggesting that MFT lesion is a direct precursor to PTC (37).

#### IV. Solid Cell Nest as Possible Stem Cells in the Thyroid Gland

Cameselle-Teijero et al. examined a case of solid cell nest hyperplasia associated with multiple PTC in a 48-year-old man with goiter. They found the same *BRAF(V600E)* mutation in both solid cell nests and adjacent papillary microcarcinoma. They concluded that solid cell nest hyperplasia is a precursor lesion of PTC (38). Reis-Filho et al. reported immunohistochemical demonstration of p63 in solid cell nest and suggested its stem cell nature (39). Furthermore, mucoepidermoid carcinoma of the thyroid and intrathyroid epithelial thymoma/carcinoma showing thymus like differentiation (ITET/CASTLE) have been postulated to originate from solid cell nests (40-42).

#### V. Benign Neoplastic and Non-Neoplastic Nodular Lesions

Benign proliferation of follicular cells in the thyroid gland can give rise to a variety of lesions, such as non-neoplastic proliferative lesions, benign hyperplastic adenomatous nodule, and follicular adenoma (43-46). Thyroid carcinomas have been reported to be associated with thyroid nodular lesions (47).

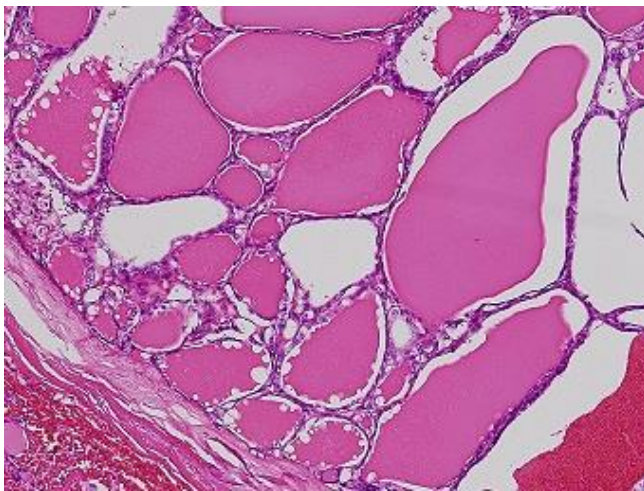


Figure 1: Low-power magnification of a thyroid nodule from a 54-year-old female patient. It is an encapsulated and invasive papillary carcinoma forming macro-follicular structures (Hematoxylin and Eosin stain, x10).

#### VI. Hyperplastic Adenomatous Nodule, Adenomatous Goiter and Dys hormonogenetic Goiter

Kuma et al. followed 140 patients who had untreated solitary thyroid nodules for an average of about 15 years and they found that majority of the nodules decreased in size (38.3% of nodules disappeared), while 13% of nodules increased in size (16). There

were 15 cases with suspicious cytology for PTC and PTC was confirmed in nine cases (including 2 incidental PTCs). The finding of only seven PTCs in 140 thyroid nodules during a 15-year follow-up period (5% in 15 years = 0.33%/year) does not indicate a high risk for thyroid carcinomas compared with latent thyroid carcinomas in autopsy thyroid glands (5-20%) and risk of incidental papillary microcarcinoma (16.7%) in surgically treated thyroid glands for unrelated benign diseases (20, 47, 48).

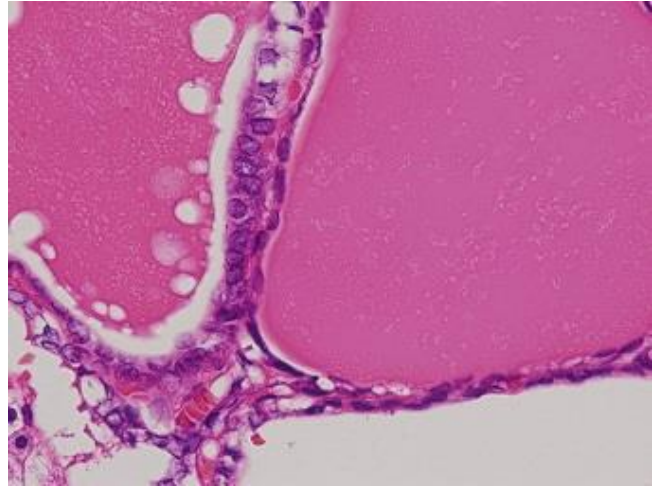


Figure 2: High-power magnification of the Figure 1 demonstrates papillary thyroid carcinoma type nuclear features only in the left field, while follicular cells in the right field contain a small pycnotic nucleus. The two different types of nuclei suggest that PTC cells in the left field may occur or invade in the preexisting thyroid nodule in the right field (Hematoxylin and Eosin stain, x40).

Couch et al. reported that, of the 18 patients with multinodular goiter who demonstrated autosomal dominant inheritance, two patients had PTC (44). There are also some reports of thyroid carcinoma arising in dys hormonogenetic goiter (50-52). Hishinuma et al. reported a high prevalence (7 out of 11) of thyroid carcinoma in patients with thyroglobulin gene mutations and they confirmed activating *BRAF* gene mutations in 2 of the 5 cases examined. They postulated that thyroglobulin mutations predispose to thyroid cancer development through activating mutations of oncogenes, although Ghossein et al. reported only 3 incidental PTCs in 56 cases of dys hormonogenetic goiter (52, 53). Mori et al. reported that the risk of incidental PTC in patients with a benign nodular thyroid lesion was 27.7% and it decreased to 7.22% when clinical cancer was excluded (54). They also found 2 of 20 cases of incidental cancer occurring within a nodule (54). Arora et al. reported that 2% of thyroid malignancy arises within a preexisting benign thyroid nodule (55). Figure 1 is from a 54-year-old female with encapsulated PTC, follicular variant, showing that the tumor contains follicular structures covered with pycnotic small nuclei or large irregular nuclei of typical PTC type nuclear features (Fig 2), as if PTC occurs in the nodule or invades into preexisting AN. Although the incidence of PTC in nodular thyroid lesions is not high, PTC found within a thyroid nodule may indicate that the thyroid nodular lesion may serve as a precursor lesion of thyroid carcinomas. The prevalence of thyroid carcinoma in solitary cold nodule was reported to be from 7.3% to 17%, and from 3.5% to 15% in multinodular goiter in literature (47, 56-58). Fiore et al. analyzed 33,774 patients with cold thyroid nodules and found that the prevalence of PTC increases with TSH, being the highest in patients with serum TSH in the upper limit of the normal range and

the lowest in patients with below normal TSH values (59). They concluded that TSH may have a significant impact on thyroid carcinogenesis and further suggest that thyroid autonomy, by reducing TSH, may slow down cancer progression and reduce the probability that mutated oncogenes may cause clinically detectable cancer (59).

## VII. Follicular Adenoma and Atypical Adenoma

Fusco et al. analyzed encapsulated and non-invasive thyroid nodules with borderline morphological features of PTC, so-called well differentiated tumor of uncertain malignant potential (WDT-UMP) or encapsulated follicular variant PTC (60, 61). They concluded that RET activation closely parallels the areas of tumors with cytological alterations and further commented that it is possible that such foci may precede to the development of invasive PTC (60). Arora et al. examined gene expression profiles and clarified that follicular adenomas and Hürthle cell adenomas have similarities to both benign and malignant tumors, suggesting that some of these tumors are premalignant (55, 62). In addition, 10% of surgically excised follicular tumors that are encapsulated follicular lesions with nuclear atypia are WDT-UMP. Arora et al. concluded that these tumors could be precursors of carcinoma (55, 62).

The term "atypical adenoma" has been variably used to refer to FA exhibiting high cellularity, nuclear atypia or unusual histologic patterns (20, 47). Molecular features were analyzed in atypical adenoma, typical adenoma and FTC by Tzen et al. and they concluded that atypical adenoma is a precursor of UC because two cases of atypical adenoma showed a *p53* point mutation in codon 273, a common mutation in various human cancers, including UC (63). However, Revera et al. examined 8 cases of non-invasive encapsulated tumor with high-grade histology and found that these tumors did not recur in a median follow up of 11.9 years, Nikiforova et al. suggested that FA with *PAX8/PPAR $\gamma$*  rearrangements might be non-invasive FTC in which the invasive nature of tumor was overlooked, while Xing et al. commented that the common occurrence of *RAS* mutations in FA, a presumed premalignant lesion, suggests that activated *RAS* may have a role in early follicular cell tumorigenesis (2, 9, 64). *RET/PTC* rearrangements have been reported in FA, and an association between *RET/PTC* and a high growth rate was recently found (13-15).

## VIII. Papillary Microcarcinoma (So-Called Papillary Microtumor)

Papillary thyroid microcarcinoma is defined as PTC of smaller than 1.0 cm in diameter (20). It is a common incidental finding in surgical specimens of the thyroid gland resected for unrelated benign diseases and in autopsy thyroid glands (20, 47, 48). This microtumor is currently labeled as cancer and some have suggested that it may be an early stage in the carcinogenesis of the PTC lineage (12, 65, 66). It occurs in thyroid nodular lesions as a cancer in adenoma (Fig. 1) or in normal looking thyroid as a de novo cancer (Fig. 3).

Papillary microtumors may have lymph node metastasis, recurrence and distant metastasis in a very small number of patients, but the majority of them are indolent in nature (66-73). Some investigators reported their observation trials of patients with this tumor and proved that the majority of papillary microtumors did not grow in size and did not show progression in terms of tumor stage; therefore, immediate aggressive surgical treatment is

not necessary for this extremely low-risk thyroid lesion (70, 72). Kakudo et al. proposed a new classification of thyroid follicular cell tumors, in which those biologically benign lesions currently labeled as carcinoma (papillary microcarcinoma, encapsulated PTC, capsular invasion only FTC, WDT-UMP, FT-UMP) are placed in a borderline category between benign and low-risk WDCs (74-77). International experts of thyroid pathology have proposed renaming papillary microcarcinoma as papillary microtumor without using cancer terminology (78).

## IX. Encapsulated Well-differentiated Thyroid Carcinomas

Most encapsulated thyroid carcinomas in the WDC category, even though they are currently labelled as cancer, are indolent and not life-threatening (74-77, 79-84). Piana et al. collected 108 cases of thyroid carcinoma with capsulation (including FTC and PTC) and found that no tumor-related death occurred for an approximately 12-year follow-up period (84). Sugino et al. and Ito et al. separately analyzed their PTC patients who were treated for benign nodules; surprisingly the disease-free survival rate of those incompletely treated patients was better than that of PTC patients who were radically treated for cancer (80, 81). It has been emphasized in our previous reviews that the encapsulated PTC, WDT-UMP, follicular tumor of uncertain malignant potential (FT-UMP), capsular invasion only FTC, and papillary microcarcinoma, are not genuine cancers in terms of prognosis and may belong to a borderline category (well-differentiated tumor of uncertain behavior) or a precancerous lesion (74-77). Recently, indolent lesion of epithelial origin (IDLE) has been proposed by Esserman et al. for these lesions currently labeled as cancers and their precursors that are unlikely to cause harm if they are left untreated (85). We believe the new concept of IDLE introduced by Esserman and borderline or precancerous lesions in the thyroid tumor classification introduced by our group make it possible to adopt the current knowledge on genetic changes of thyroid carcinomas into the multistep carcinogenesis of thyroid follicular cell tumors, from normal follicular cells to hyperplastic proliferative lesions, precancerous (borderline) benign neoplasia, non-invasive carcinoma, early invasive cancer, invasive cancer with nodal metastasis, locally advanced cancer, advanced cancer with distant metastasis, PDC, UC and patient death (12).

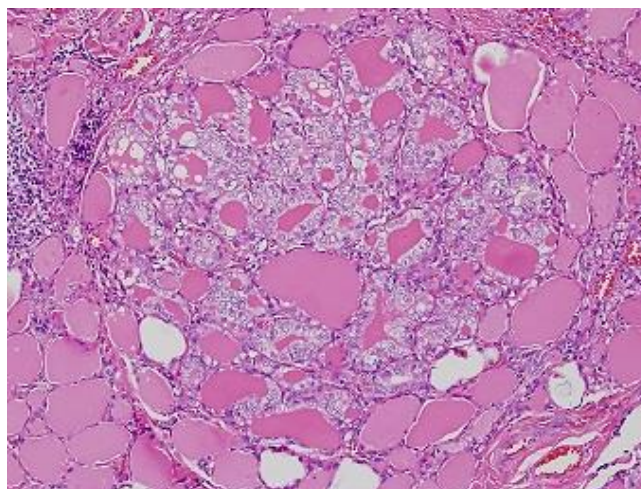


Figure 3: Microscopic papillary carcinoma found in the non-nodular thyroid parenchyma of a 50 years female patient. Papillary carcinoma occurs as if it is de novo cancer. Note papillary thyroid carcinoma type

nuclear features, different from normal thyroid in the back ground (Hematoxylin and Eosin stain, x20).

## Conclusions

*RET/PTC* rearrangements, *PAX8/PPAR $\gamma$*  rearrangements and *RAS* mutations may be found in thyroid neoplasms in both benign and malignant tumors, and these genetic alterations occur as initiation steps rather than as progression events. Additional genetic and epigenetic alterations are required to transform benign precursor lesions into truly malignant thyroid carcinomas. Therefore, *RET/PTC* rearrangements, *PAX8/PPAR $\gamma$*  rearrangements and *RAS* mutations are not firm evidence of malignancy in thyroid cytology and pathology. This is important for the clinical management of patients with thyroid nodules and this borderline category diagnosis will possibly reduce unnecessary surgical treatment for those patients with mutation-positive thyroid nodules. Thyroid nodules with those mutations may be borderline lesions equivalent to tubular adenoma with *APC* mutations in the alimentary tract. Since tubular adenomas with *APC* mutations are histopathologically diagnosed as benign or dysplastic (not cancer) lesions until invasive growth beyond their anatomical structures is identified, thyroid nodules confined to the thyroid gland become borderline lesions and only tumors with extrathyroid invasion or metastasis belong to the malignant category in this diagnostic schema, which has been proposed in our previous studies (74-77).

All of the thyroid lesions discussed in the present review may serve as early steps in thyroid multistep carcinogenesis and we believe that proper identification of these precursor thyroid lesions will help reduce over-diagnosis and over-treatment of patients with thyroid nodules.

## References:

- Barrett JC. Mechanisms of multistep carcinogenesis and carcinogen risk assessment. *Environment Health Perspect* 1993; 100:9-20.
- Nikiforova MN, Lynch RA, Biddinger PW, Alexander EK, Dorn GW 2nd, Tallini G, Kroll TG, Nikiforov YE. RAS point mutations and PAX8-PPAR gamma rearrangement in thyroid tumors: evidence for distinct molecular pathways in thyroid follicular carcinoma. *J Clin Endocrinol Metab* 2003; 88:2318-26.
- Kondo T, Ezzat S, Asa SL. Pathogenetic mechanisms in thyroid follicular-cell neoplasia. *Nat Rev Cancer* 2006; 6:292-306.
- Parameswaran R, Brooks S, Sadler GP. Molecular pathogenesis of follicular cell derived thyroid cancers. *Int J Surg* 2010; 8:186-93.
- Caria P, Vanni R. Cytogenetic and molecular events in adenoma and well-differentiated thyroid follicular-cell neoplasia. *Cancer Genet Cytogenet* 2010; 203:21-9.
- Gauchotte G, Phillippe C, Lacomme S, Leotard B, Wissler MP, Allou L, Toussaint B, Klein M, Vignaud JM, Bressenot A. BRAF, p53 and SOX2 in anaplastic thyroid carcinoma: evidence for multistep carcinogenesis. *Pathol* 2011; 43:447-52.
- Soares P, Lima J, Preto A, Castro P, Vinagre J, Celestino R, Couto JP, Prazeres H, Eloy C, Máximo V, Sobrinho-Simões M. Genetic alterations in poorly differentiated and undifferentiated thyroid carcinomas. *Curr genomics* 2011; 12:609-17.
- Nikiforov YE, Nikiforova MN. Molecular genetics and diagnosis of thyroid cancer. *Nat Rev Endocrinol* 2011; 30:569-80.
- Xing M. Molecular pathogenesis and mechanisms of thyroid cancer. *Nat Rev Cancer* 2013; 13:184-99.
- Phay JE, Ringel MD. Metastatic mechanisms in follicular cell-derived thyroid cancer. *Endocr Relat Cancer* 2013; 20:R307-19.
- Omur O, Baran Y. An update on molecular biology of thyroid cancers. *Crit Rev Oncol Hematol* 2014; 90:233-52.
- Kakudo M, Kondo T, Kakudo K. Thyroid follicular cell neoplasms in multistep carcinogenesis. *J Basic Clin Med* 2014; 3:19-27.
- Ishizaka Y, Kobayashi S, Ushijima T, Hirohashi S, Sugimura T, Nagao M. Detection of ret/TPC/PTC transcripts in thyroid adenomas and adenomatous goiter by an RT-PCR method. *Oncogene* 1991; 6:1667-72.
- Guerra A, Sapio MR, Marotta V, Campanile E, Moretti MI, Deandrea M, Motta M, Limone PP, Fenzi G, Rossi G, Vitale M. Prevalence of RET/PTC rearrangement in benign and malignant thyroid nodules and its clinical application. *Endocr J* 2011; 58:31-8.
- Sapio MR, Guerra A, Marotta V, Campanile E, Formisano R, Deandrea M, Motta M, Limone PP, Fenzi G, Rossi G, Vitale M. High growth rate of benign thyroid nodules bearing RET/PTC rearrangements. *J Clin Endocrinol Metab* 2011; 96:E916-9.
- Kuma K, Matsuzuka F, Kobayashi A, Hirai K, Morita S, Miyauchi A, Katayama S, Sugawara M. Outcome of long standing solitary thyroid nodules. *World J Surg* 1992; 16:583-7.
- Nou E, Kwong N, Alexander LK, Cibas ES, Marqusee E, Alexander EK. Determination of the optimal time interval for repeat evaluation after a benign thyroid nodule aspiration. *J Clin Endocrinol Metab* 2014; 99:510-6.
- Lee S, Skelton TS, Zheng F, Schwartz KA, Perrier ND, Lee JE, Bassett RL, Ahmed S, Krishnamurthy S, Busaidy NL, Grubbs EG. The biopsy-proven benign thyroid nodule: is long term follow-up necessary? *J Am Coll Surg* 2013; 217:81-8.
- Lim DJ, Kim JY, Baek KH, Kim MK, Park WC, Lee JM, Kang MI, Cha BY. Natural course of cytologically benign thyroid nodules: Observation of ultrasonographic changes. *Endocrinol Metab* 2013; 28:110-8.
- DeLellis RA, Lloyd RV, Heitz PU, Eng C. Tumours of Endocrine Organs, World Health Organization Classification of Tumors; Pathology and Genetics. Lyon: IARC Press; 2004.
- Wolfe HJ, Melvin KE, Cervi-Skinner SJ, Saadi AA, Juliar JF, Jackson CE, Tashjian AH Jr. C-cell hyperplasia preceding medullary thyroid carcinoma. *N Engl J Med* 1973; 30:437-41.
- DeLellis RA, Nunnemacher G, Wolfe HJ. C-cell hyperplasia. An ultrastructural analysis. *Lab Invest* 1977; 36:237-48.
- Kakudo K. Ultrastructural study of medullary carcinoma of the thyroid. *Med J Osaka Univ* 1977; 27:101-15.
- Kakudo K, Takahashi M, Ito Y. Multiple endocrine neoplasia syndrome in Endocrine pathology, differential diagnosis and molecular advances, second edition, editor Lloyd RV, Springer, New York, 2010; p493-521.
- Abend M, Pfeiffer RM, Ruf C, Hatch M, Bogdanova TI, Tronko MD, Hartmann J, Meineke V, Mabuchi K, Brenner AV. Iodine-131 dose-dependent gene expression: alters in both normal and tumor thyroid tissues of post-Chernobyl thyroid cancers. *Br J Cancer* 2013; 109:2286-94.

26. Hirabayashi RN, Lindsay S. The relation of thyroiditis and chronic thyroiditis. *Surg Gynecol Obstet* 1965; 121:243-52.
27. Okayasu I, Fujiwara M, Hara Y, Tanaka Y, Rose NR. Association of chronic lymphocytic thyroiditis and thyroid papillary carcinoma. A study of surgical cases among Japanese, and white and African Americans. *Cancer* 1995; 76:2312-8.
28. Wirtschaffner A, Schmidt R, Rosen D, Kundu N, Santoro M, Fusco A, Mulhaupt H, Atkins JP, Rosen MR, Keane WM, Rothstein JL. Expression of the RET/PTC fusion gene as a marker for papillary carcinoma in Hashimoto's thyroiditis. *Laryngoscope* 1997; 107:95-100.
29. Di Pasquale M, Rothstein JL, Palazzo JP. Pathologic features of Hashimoto's-associated papillary thyroid carcinomas. *Hum Pathol* 2001; 32:24-30.
30. Arif S, Balanes A, Diaz-Cano SJ. Hashimoto's thyroiditis shares features with early papillary thyroid carcinoma. *Histopathol* 2002; 41:357-62.
31. Nikiforova MN, Caudill CM, Biddinger P, Nikiforov YE. Prevalence of RET/PTC rearrangements in Hashimoto's thyroiditis and papillary thyroid carcinomas. *Int J Surg Pathol* 2002; 10:15-22.
32. Replinger D, Bargren A, Zhang YW, Adler JT, Haymart M, Chen H. Is Hashimoto's thyroiditis a risk factor for papillary thyroid cancer? *J Surg Res* 2008; 150:49-52.
33. Wakasa T, Shintaku M, Tanaka S, Yamada K, Li Y, Kakudo K. Morphological changes of follicular cells in Hashimoto's disease. A possible cause of overdiagnosis in cytology. *J Basic Clin Med* 2013; 2:12-6.
34. Chiu MH, Cassol CA, Asa SL, Mete O. Follicular epithelial dysplasia of the thyroid: morphological and immunohistochemical characterization of a putative preneoplastic lesion to papillary thyroid carcinoma in chronic lymphocytic thyroiditis. *Virch Arch* 2013; 462:557-63.
35. Kato I, Tajima K, Suchi T, Aozasa K, Matsuzuka F, Kuma K, Tominaga S. Chronic thyroiditis as a risk factor of B-cell lymphoma in the thyroid gland. *Jpn J Cancer Res* 1985; 76:1085-90.
36. Stein SA, Wartofsky L. Primary thyroid lymphoma: a clinical review. *J Clin Endocrinol Metab* 2013; 98:3131-8.
37. Frank R, Baloch ZW, Genittle C, Watt CD, LiVolsi VA. Multifocal fibrosing thyroiditis and its association with papillary thyroid carcinoma using BRAF pyrosequencing. *Endocr Pathol* 2014; 25:236-40.
38. Cameselle-Tejiero J, Abdulkader I, Perez-Becerra R, Vazques-Boquete A, Alberte-Lista L, Ruiz-Ponte C, Forteza J, Sobrinho-Simões M. BRAF mutation in solid cell nest hyperplasia with papillary thyroid carcinoma. A precursor lesion? *Hum Pathol* 2009; 40:1029-35.
39. Reis-Filho JS, Preto A, Soares P, Ricardo S, Cameselle-Tejiero J, Sobrinho-Simões M. p63 expression in solid cell nests of the thyroid: further evidence for a stem cell origin. *Mod Pathol* 2003; 16:43-8.
40. Katoh R, Sugai T, Ono S, Takayama K, Tomichi N, Kurihara H, Takamatsu M. Mucoepidermoid carcinoma of the thyroid gland. *Cancer* 1990; 65:2020-7.
41. Reinmann JD, Dorfman DM, Nose V. Carcinoma showing thymus-like differentiation of thyroid (CASTLE): a comparative study: evidence of thymic differentiation and solid cell nest origin. *Am J Surg Pathol* 2006; 30:994-1001.
42. Kakudo K, Bai Y, Ozaki T, Homma K, Ito Y, Miyauchi A. Intrathyroid epithelial thymoma (ITET) and carcinoma showing thymus-like differentiation (CASTLE): CD5-positive neoplasms mimicking squamous cell carcinoma of the thyroid. *Histol Histopathol* 2013; 28:543-56.
43. Cooper DS, Axelrod L, DeGroot LJ, Vickery AL Jr, Maloof F. Congenital goiter and development of metastatic follicular carcinoma with evidence for a leak of nonhormonal iodine: Clinical, pathological, kinetic, and biochemical studies and a review of the literature. *J Clin Endocrinol Metab* 1981; 52:294-306.
44. Couch RM, Hughes IA, Desa DJ, Schiffrin A, Guyda H, Winter JS. An autosomal dominant form of adolescent multinodular goiter. *Am J Hum Genet* 1986; 39:811-6.
45. Paschke R. Molecular pathogenesis of nodular goiter. *Langenbecks Arch Surg* 2011; 396:1127-36.
46. Colin IM, Denef JF, Lengele B, Many MC, Gérard AC. Recent insights into the cell biology of thyroid angiofollicular units. *Endocr Rev* 2013; 34:209-38.
47. Kharn A, Nose V. Pathology of thyroid gland in *Endocrine pathology, Differential diagnosis and molecular advances*, second edition, editor Lloyd RV, Springer, New York, 2010; p181-236.
48. Fink A, Tomlinson G, Freeman JL, Rosen IB, Asa SL. Occult micropapillary carcinoma associated with benign follicular thyroid disease and unrelated thyroid neoplasms. *Mod Pathol* 1996; 9:816-20.
49. Yashiro T, Ito K, Akiba M, Kanaji Y, Obara T, Fujimoto Y, Hirayama A, Nakajima H. Papillary carcinoma of the thyroid arising from dyshormonogenetic goiter. *Endocrinol Jpn* 1987; 34:955-64.
50. Medeiros-Neto G, Gil-Da-Costa MJ, Santos CL, Medina AM, Silva JC, Tsou RM, Sobrinho-Simões M. Metastatic thyroid carcinoma arising from congenital goiter due to mutation in the thyroperoxidase gene. *J Clin Endocrinol Metab* 1998; 83:4162-6.
51. Camargo R, Limbert E, Gillam M, Henriques MM, Fernandes C, Catarino AL, Soares J, Alves VA, Kopp P, Medeiros-Neto G. Aggressive metastatic follicular thyroid carcinoma with anaplastic transformation arising from a long-standing goiter in patient with Pendred's syndrome. *Thyroid* 2001; 11:981-8.
52. Hishimura A, Fukata S, Kakudo K, Murata Y, Ieiri T. High incidence of thyroid cancer in long-standing goiters with thyroglobulin mutations. *Thyroid* 2005; 19:1079-84.
53. Ghossein RA, Rosai J, Heffess C. Dyshormonogenetic goiter: a clinicopathologic study of 56 cases. *Endocr Pathol* 1997; 8:283-92.
54. Mori I, Miyauchi A, Kuma S, Tang W, Kakudo K. Thyroid nodular lesion: Analysis of cancer risk based on Kuma hospital experience. *Pathol Int* 2003; 53:579-83.
55. Arora N, Scognamiglio T, Zhu B, Fahey TJ 3rd. Do benign thyroid nodules have malignant potential? An evidence-based review. *World J Surg* 2008; 32:1237-46.
56. Sachmechi I, Miller E, Varatharajah R, Chernys A, Carroll Z, Kissin E, Rosner F. Thyroid carcinoma in single cold nodules and in cold nodules of multinodular goiters. *Endocr Pract* 2000; 6:5-7.
57. Negro R, Valcarvi R, Toiulis KA. Incidental thyroid cancer in toxic and nontoxic goiter: Is TSH associated with malignancy rate? Results of meta-analysis. *Endocr Pract* 2013; 19:212-8.
58. Brito JP, Yarur AJ, Prokop LJ, McIver B, Murad MH, Montori VM. Prevalence of thyroid cancer in multinodular goiter versus single nodule: a systematic review and meta-analysis. *Thyroid* 2013; 23:449-55.
59. Fiore E, Rago T, Provenzale MA, Scutari M, Ugolini C, Basolo F, Di Coscio G, Berti P, Grasso L, Elisei R, Pinchera

- A, Vitti P. Lower levels of TSH are associated with a lower risk of papillary thyroid cancer in patients with thyroid nodular disease: thyroid autonomy may play a protective role. *Endocr Relat Cancer* 2009; 16:1251-60.
60. Fusco A, Chiappetta G, Hui P, Garcia-Rostan G, Golden L, Kinder BK, Dillon DA, Giuliano A, Cirafici AM, Santoro M, Rosai J, Tallini G. Assessment of RET/PTC oncogene activation and clonality in thyroid nodules with incomplete morphological evidence of papillary carcinoma: a search for the early precursors of papillary cancer. *Am J Pathol* 2002; 160:2157-67.
  61. Williams ED, Guest editorial. Two proposals regarding the terminology of thyroid tumors. *Int J Surg Pathol* 2000; 8:181-3.
  62. Arora N, Scognamiglio T, Lubitz CC, Moo TA, Kato MA, Zhu B, Zarnegar R, Chen YT, Fahey TJ 3rd. Identification of borderline thyroid tumors by gene expression array analysis. *Cancer* 2009; 115:5421-31.
  63. Tzen CY, Huang YW, Fu YS. Is atypical follicular adenoma of the thyroid a preinvasive malignancy? *Human Pathol* 2003; 34:666-9.
  64. Rivera M, Ricarte-Filho J, Patel S, Tuttle M, Shaha A, Shah JP, Fagin JA, Ghossein RA. Encapsulated thyroid tumors of follicular cell origin with high grade features (high mitotic rate/tumor necrosis): a clinicopathologic and molecular study. *Hum Pathol* 2010; 41:172-80.
  65. Sugg SL, Ezzat S, Rosen IB, Freeman JL, Asa SL. Distinct multiple RET/PTC gene rearrangements in multifocal papillary thyroid neoplasia. *J Clin Endocrinol Metab* 1998; 83:4116-22.
  66. Kakudo K, Mori I, Liu Z, Zuo H, Kakudo M, Wakasa T. Papillary microcarcinoma and microtumor of thyroid gland. *J Basic Clin Med* 2013; 2:1-6.
  67. Zuo H, Tang W, Yasuoka H, Nakamura Y, Ito Y, Miyauchi A, Kakudo K. A review of 227 cases of small papillary thyroid carcinoma. *Eur J Surg Oncol* 2007; 33:370-5.
  68. Hay ID, Grant CS, van Heerden JA et al. Papillary thyroid microcarcinoma: a study of 535 cases observed in a 50-year period. *Surg* 1992; 112:1139-47.
  69. Hay ID, Hutchinson ME, Gonzalez-Losada T, Goellner JR, Ebersold JR, Bergstralh EJ. Papillary thyroid microcarcinoma: a study of 900 cases observed in 60-year period. *Surgery* 2008; 144:987-8.
  70. Ito Y, Miyauchi A. A therapeutic strategy for incidentally detected papillary microcarcinoma of the thyroid. *Nat Clin Pract Endocrinol Metab* 2007; 3:240-8.
  71. Arora N, Tubendian HK, Kato MA, Moo TA, Zarnegar R, Fahey TJ 3rd. Papillary thyroid carcinoma and microcarcinoma: is there a need to distinguish the two? *Thyroid* 2009; 19:473-7.
  72. Sugitani I, Toda K, Yamada K, Yamamoto N, Ikenaga M, Fujimoto Y. Three distinct kinds of papillary thyroid microcarcinoma should be recognized: our treatment strategies and outcomes. *World J Surg* 2010; 34:1223-31.
  73. Mehannan H, Al-Maqbili T, Carter B, Martin E, Campaign N, Watkinson J, McCabe C, Boelaert K, Franklyn JA. Differences in the recurrence and mortality outcomes rates of incidental and nonincidental papillary thyroid microcarcinoma: a systematic review and meta-analysis of 21329 person-years of follow-up. *J Clin Endocrinol Metab* 2014; 99:2834-43.
  74. Kakudo K, Bai Y, Katayama S, Hirokawa M, Ito Y, Miyauchi A, Kuma K. Classification of thyroid follicular cell tumors of the thyroid gland: analysis involving Japanese patients from one institute. *Pathol Int* 2009; 59:359-67.
  75. Kakudo K, Bai Y, Liu Z, Li Y, Ito Y, Ozaki T. Classification of thyroid follicular cell tumors: with special reference to borderline lesions. *Endocr J* 2011; 59:1-12.
  76. Liu Z, Zhou G, Nakamura M, Koike E, Li Y, Ozaki T, Mori I, Taniguchi E, Kakudo K. Encapsulated follicular thyroid tumor with equivocal nuclear changes, so-called well differentiated tumor of uncertain malignant potential: a morphological, immunohistochemical, and molecular appraisal. *Cancer Sci* 2011; 102:288-94.
  77. Kakudo K, Bai Y, Liu Z, Ozaki T. Encapsulated papillary thyroid carcinoma, follicular variant: a misnomer. *Pathol Int* 2012; 62:155-60.
  78. Rosai J, LiVolsi VA, Sobrinho-Simoes M, Williams ED. Renaming papillary microcarcinoma of the thyroid gland: the Porto proposal. *Int J Surg Pathol* 2003; 11:249-51.
  79. Van Heerden JA, Hay ID, Goellner JR, Salomao D, Ebersold JR, Bergstralh EJ, Grant CS. Follicular thyroid carcinoma with capsular invasion alone: a nonthreatening malignancy. *Surg* 1992; 112:1130-8.
  80. Sugino K, Ito K, Mimura T, Ozaki O, Kawano M, Kitamura Y, Iwabuchi H. The enucleation of thyroid tumors indeterminate before surgery as papillary thyroid carcinoma: should immediate reoperation be performed? *Surg Today* 1994; 24:305-8.
  81. Ito Y, Higashiyama T, Takamura Y, Miya A, Kobayashi K, Matsuzuka F, Kuma K, Miyauchi A. Long-term follow-up for patients with papillary thyroid carcinoma treated as benign nodules. *Anticancer Res* 2007; 27:1039-43.
  82. Ito Y, Hirokawa M, Uruno T, Kihara M, Higashiyama T, Takamura Y, Miya A, Kobayashi K, Matsuzuka F, Miyauchi A. Biological behavior and prognosis of encapsulated papillary carcinoma of the thyroid: experience of a Japanese hospital for thyroid care. *World J Surg* 2008; 32:1789-94.
  83. Rivera M, Tuttle RM, Patel S, Shaha A, Shah JP, Ghossein RA. Encapsulated papillary thyroid carcinoma: a clinic-pathologic study of 106 cases with emphasis on its morphological subtypes (histologic growth pattern). *Thyroid* 2009; 19:119-27.
  84. Piana S, Frasoldati A, Di Felice E, Gardini G, Tallini G, Gardini G, Tallini G, Rosai J. Encapsulated well-differentiated follicular-patterned thyroid carcinomas do not play a significant role in the fatality rates from thyroid carcinoma. *Am J Surg Pathol* 2010; 34:868-72.
  85. Esserman LJ, Thompson IM, Reid B, Nelson P, Ransohoff DF, Welch HG, Hwang S, Berry DA, Kinzler KW, Black WC, Bissell M, Parnes H, Srivastava S. Addressing overdiagnosis and overtreatment in cancer: a prescription for change. *Lancet Oncol* 2014; 15:e234-42.